Systematic review

doi:10.1111/codi.14547

Sigmoid resection for diverticular disease – to ligate or to preserve the inferior mesenteric artery? Results of a systematic review and meta-analysis

R. Cirocchi*, G. Popivanov†, G. A. Binda‡, B. M. Henry§, K. A. Tomaszewski¶, R. J. Davies and S. Di Saverio****

*Department of Surgical Science, University of Perugia, Piazza dell'Università 1, Perugia, Italy, †Department of Surgery, Military Medical Academy, Sofia, Bulgaria, ‡Department of Surgery, Galliera Hospital, Genoa, Italy, §Cincinnati Children's Hospital Medical Center, Cincinnati, Ohio, USA, ¶International Evidence-Based Anatomy Working Group, Krakow, Poland, and **Cambridge Colorectal Unit, Addenbrooke's Hospital, Cambridge University Hospitals NHS Trust, Cambridge, UK

Received 21 September 2018; accepted 9 December 2018; Accepted Article Online 4 January 2019

Abstract

Aim In colorectal cancer, ligation of the inferior mesenteric artery (IMA) is a standard surgical approach. In contrast, ligation of the IMA is not mandatory during treatment of diverticular disease. The object of this meta-analysis was to assess if preservation of the IMA reduces the risk of anastomotic leakage.

Method A search was performed up to August 2018 using the following electronic databases: MEDLINE/PubMed, ISI Web of Knowledge and Scopus. The measures of treatment effect utilized risk ratios for dichotomous variables with calculation of the 95% CI. Data analysis was performed using the meta-analysis software Review Manager 5.3.

Results Eight studies met the inclusion criteria and were included in the meta-analysis: two randomized controlled trials (RCTs) and six non-RCTs with 2190 patients (IMA preservation 1353, ligation 837). The rate of anastomotic leakage was higher in the IMA ligation group (6%) than the IMA preservation group (2.4%), but this difference was not statistically significant [risk ratio (RR) 0.59, 95% CI 0.26–1.33, I^2 = 55%]. The conversion to laparotomy was significantly lower in the IMA ligation group (5.1%) than in the IMA preservation group (9%) (RR 1.74, 95% CI 1.14–2.65, I^2 = 0%). Regarding the other outcomes (anastomotic bleeding, bowel injury and splenic damage), no significant differences between the two techniques were observed.

Conclusion This meta-analysis failed to demonstrate a statistically significant difference in the anastomotic leakage rate when comparing IMA preservation with IMA ligation. Thus, to date there is insufficient evidence to recommend the IMA-preserving technique as mandatory in resection for left-sided colonic diverticular disease.

Keywords Left-sided diverticular disease, sigmoid resection, ligation/preservation of inferior mesenteric artery

Introduction

Sigmoid resection is the most frequent surgical intervention in complicated diverticular disease. Anastomotic leakage represents one of the most serious postoperative complications in colorectal surgery. The colorectal anastomosis should be tension-free, well vascularized and appropriately orientated in order to have the greatest chance of healing [1]. The arterial blood supply of the sigmoid colon comes from the inferior mesenteric artery (IMA), which originates from the aorta and divides into the left colic artery and two to six sigmoid arteries, which enter the sigmoid mesocolon [2,3]. The terminal branch of the IMA is the superior rectal artery [4,5]. Collaterals are reported to occur in 60% of individuals at the splenic flexure (Griffith's point) and in 50% of individuals in the upper rectum (Sudeck's point) [6]. This is important, as adequate blood supply to the anastomosis is one of the most important factors influencing its healing. From an oncological point of view, high ligation of the IMA is a cornerstone technical step [7,8], but in the surgical treatment of diverticular disease ligation is not mandatory [9]. Some studies have suggested that preservation of the IMA may reduce the risk of

Correspondence to: G. Popivanov, MD, PhD, Department of Surgery, Military Medical Academy, Sv. Georgi Sofiiski Str. 3, 1606 Sofia, Bulgaria.
E-mail: gerasimpopivanov@rocketmail.com

anastomotic leakage (by preservating the anastomotic blood supply) [10] and the rate of sigmoidectomy syndrome (by avoiding damage to the underlying autonomic nerves in the para-aortic region) [11].

In 2011, a systematic review and meta-analysis of four studies was performed. We have updated this systematic review and meta-analysis with the inclusion of new studies [12].

Method

This review was performed in accordance with the Preferred Reporting Items for Systematic Reviews and Meta-Analyses (PRISMA) statement [13]. The protocol of the study was registered and published on the PROSPERO (International Prospective Register of Systematic Reviews) website (CRD42018104566).

Inclusion criteria

Types of studies
Randomized controlled trials (RCTs) and nonrandomized studies.

Types of participants
Adults hospitalized for diverticular disease irrespective of race, gender, socioeconomic status, health status or geographical location.

Types of interventions
IMA preserving versus high ligation (at the origin of IMA) and low ligation (distal to the origin of left colic artery) during left colonic or sigmoid resection for diverticular disease.

Types of outcome measures

Primary outcomes
Anastomotic leakage and conversion from laparoscopic to open surgery.

Secondary outcomes
Anastomotic bleeding, bowel injury, splenic injury, ureteric injury, pancreatic injury, damage to the iliac vessels, rectal bleeding, reoperation rates and postoperative defaecatory disorder (sigmoidectomy syndrome).

Search methods for identification of studies

A systematic comprehensive search was undertaken to identify all relevant studies and articles regardless of language or publication status (published, unpublished or ongoing). We searched a wide range of databases and other sources in order to identify all relevant studies.

Electronic search
We searched the following electronic databases with specifically designed search strategies: MEDLINE/PubMed, ISI Web of Knowledge and Scopus. The following keywords were used in PubMed: 'inferior mesenteric artery', 'acute diverticulitis', 'complicated diverticulitis', 'sigmoidectomy', 'colectomy', 'superior rectal artery' and 'arterial preservation'. The search was performed up to 25 August 2018.

Searching other resources
The following websites of registers of clinical trials were also used: http://www.controlled-trials.com/mrct and https://clinicaltrials.gov/ (accessed on 25 August 2018) for ongoing trials on this topic. We manually checked the reference lists of all included studies to identify additional studies.

Data extraction

Data of interest from articles were independently extracted by RC and GB, entered into a spreadsheet and subsequently compared. Any discrepancies in data entry were discussed until a consensus was reached.

Methodological quality

We assessed the potential risk of bias for each RCT using the criteria and the 'risk of bias table', described in Chapter 8 of the *Cochrane Handbook for Systematic Reviews of Interventions*, Version 5 [14]. The methodological index for nonrandomized studies (MINORS) [15] was used to evaluate the methodological quality of the included comparative nonrandomized studies. RC and GB assessed the methodological quality of each trial independently.

Measures of treatment effect

Data were analysed for risk ratios (RRs) in the cases of dichotomous variables with a calculation of the 95% confidence interval (95% CI). Intention-to-treat analyses were performed extracting the number of patients originally allocated to each treatment group irrespective of compliance. The Mantel–Haenszel method was used for the meta-analysis. Results are presented as a forest plot.

Assessment of heterogeneity

The I^2 and chi-square tests were used for heterogeneity assessment. Substantial heterogeneity was considered when I^2 was larger than 50%. For the chi-square test we used a P-value of less than 0.10 to indicate the presence

of statistically significant heterogeneity. The outcomes were measured with continuous scales, while data of treatment effects were analyzed with the mean difference. If the trials used different scales, we standardized and combined the results (i.e. standardized mean difference).

Statistical analysis

The data analysis was performed using the meta-analysis software Review Manager (RevMan) version 5.3.5 (The Nordic Cochrane Centre, Copenhagen, The Cochrane Collaboration, 2014).

Results

Results of the search

The electronic search strategy identified 145 citations. After the initial screening of the titles and abstracts and removal of duplications, 58 titles remained, of which 15 were considered relevant [16–30]. A total of eight studies met the inclusion criteria and were included in the analysis [16–23] and seven studies were excluded [24–30] (see Appendix S1 in the online Supporting Information).

Eligible studies

Eight studies met the inclusion criteria and were included in the meta-analysis: two RCTs and six non-RCTs. They included 2190 patients, of whom 1353 had preservation of the IMA and 837 IMA ligation.

Characteristics of the studies

All studies were published between 2001 and 2018 and the patients enrolled between 1982 and 2015. Seven studies were published in Europe and one in the USA. Six studies (n = 1894 patients) reported the timing of surgical intervention: 1875 patients underwent elective surgery (99%) and 19 patients emergency surgery (1%). The most common surgical treatment was a laparoscopic sigmoid resection [1838 (84%) laparoscopic procedures versus 352 (16%) open procedures] (Table 1).

The type of IMA preservation was reported in six studies (1254 patients): Valdoni's technique [27], where all branches of the skeletonized IMA to the sigmoid and left colon are divided (three studies: 262 patients, 20.9%), peripheral IMA dissection close to the colon (two studies: 154 patients, 12.3%), peripheral IMA dissection at the level of the sigmoid vessels (one study: 102 patients, 8.13%) and a mix of peripheral IMA dissection at the level of the sigmoid vessels or close to the colon (one study: 736 patients, 58.7%) (Table 2).

The level of IMA ligation was reported in five studies (680 patients): three studies reported high ligation (410 patients, 60.3%), one study reported low ligation (157 patients, 23.1%) and one study reported a mixture of high and low ligation (113 patients, 16.6%) (Table 2).

Only De Nardi *et al.* [23] performed a covering stoma for any technical problems (clinical condition or positive air test): three in the IMA preservation group and one in the IMA ligation group.

Risk of bias in included studies

The overall quality of both RCTs was poor. Both trials mentioned the method of random sequence generation but they did not report the allocation concealment. Neither used an independent outcome evaluator nor mentioned the intention-to-treat principle (Appendix S2).

The methodological evaluation of the non-RCTs with the MINORS scale showed that two studies scored 21 points (high quality) [18,19], two had 17 points [20,23] and the other two studies scored 10 points

Table 1 Characteristics of studies included in the meta-analysis.

Authors and year of publication	Type of study	Enrolment period	Nation	No. of patients	Timing of surgical intervention (n)
De Nardi *et al.* (2018) [23]	RS	2006–2012	Italy	219	Elective (219)
Posabella *et al.* (2018) [18]	PNR	2004–2014	Switzerland	1016	Elective (1016)
Sohn *et al.*(2017) [20]	RS	2002–2015	Germany	259	Elective (257), emergency (2)
Borchert *et al.* (2015) [19]	PNR	2006–2008	Germany	213	NR
Masoni *et al.* (2012) [17]	RCT	2004–2010	Italy	107	Elective (107)
Lehmann *et al.* (2011) [21]	RS	2002–2009	USA	130	Elective (113), emergency (17)
Pignata (2006) [22]	RS	2000–2005	Italy	83	NR
Tocchi *et al.* (2001) [16]	RCT	1982–1996	Italy	163	Elective (163)

IMA, inferior mesenteric artery; NR, not reported; PNR, prospective nonrandomized controlled trial; RS, retrospective study.

(poor quality) [21,22] (Appendix S3). In the non-RCTs there was a possible selection bias associated with the decision to preserve or to ligate the IMA. Only two studies reported that this decision was left to the discretion of the surgeon [18,19].

Another possible source of bias is the experience of the operating surgeon. For example, in the study by Posabella *et al.* the operations were performed by an attending surgeon, consultant or resident under supervision [18].

Different classifications of the severity of diverticulitis were reported in four studies (Appendix S4a,b): the Hansen–Stock classification [19,20] and types of complications [16,18].

There was heterogeneity regarding the inclusion/exclusion criteria: three studies excluded the emergency setting [17,18,23] whereas in the other studies [19–22] some of the included patients had emergency resections (Appendix S5). The definition of anastomotic leakage (clinical versus radiological) was reported in five studies (Appendix S6).

Results of analysis

Anastomotic leakage

Seven studies reported the anastomotic leakage rate (1864 participants) [16,18–23]. This rate was higher in the IMA ligation group (high or low) (6%, 47/784) than the IMA preservation group (2.4%, 31/1 299), but the result was not statistically significant (RR 0.59, 95% CI 0.26–1.33) particularly with a background of high heterogeneity (I^2 = 55%) (Fig. 1).

Sensitivity analysis was performed in three studies [18,20,22] that reported only laparoscopic resection (1.3%, 12/916, *vs* 2.7%, 12/442). The difference was not statistically significant (RR 0.54, 95% CI 0.23–1.26; n = 1358 participants) with a lack of the heterogeneity in these studies (I^2 = 0%) (Fig. 2).

It was not possible to perform a sensitivity analysis regarding the type of anastomotic leakage (radiological versus clinical). In fact, only Tocchi *et al.* [16] reported radiological evidence of anastomotic leakage in six patients who underwent IMA preservation (7%) versus 14 in the IMA ligation group (18.1%) (P = 0.02). Clinical anastomotic leakage was reported in one patient in the preservation group (2.3%) and eight patients in the ligation group (10.4%) (P = 0.03).

Conversion from laparoscopic to open surgery

Four studies [17–20] (n = 1463 participants) reported the conversion rate, which was significantly lower in the IMA ligation group (5.1%, 28/553) than in the IMA preservation group (9%, 93/1037) (RR 1.74, 95% CI 1.14–2.65, I^2 = 0%) (P = 0.01) (Fig. 3).

Secondary outcomes

No significant difference was found between the two techniques with regard to secondary outcomes (anastomotic bleeding, bowel injury and splenic damage) (Table 3). Other secondary outcomes were also

Table 2 Characteristics of surgical treatment in included studies.

Authors and year of publication	Access to surgical treatment (no. of patients, %)		Surgical treatment of IMA (no. of patients)		Level of peripheral dissection (IMA-preserving)	Level of IMA ligation
	Open	Laparoscopy	Preserving	Ligation		
De Nardi *et al.* (2018) [23]	87 (39.73%)	132 (60.27%)	153	66	Valdoni's technique	NR
Posabella *et al.* (2018) [18]	0	1016 (100%)	736	280	Close colon or sigmoid mesocolon vessels	High
Sohn *et al.*(2017) [20]	0	259 (100%)	102	157	Sigmoid mesocolon vessels	Low
Borchert *et al.* (2015) [19]	25 (11.74%)	188 (88.26%)	100	113	Close colon	High/low
Masoni *et al.* (2012) [17]	0	107 (100%)	54	53	Close colon	High
Lehmann *et al.* (2011) [21]	77 (59.23%)	53 (60.77%)	44	86	NR	NR
Pignata (2006) [22]	0	83 (100%)	23	60	Valdoni's technique	NR
Tocchi *et al.* (2001) [16]	163 (100%)	0	86	77	Valdoni's technique	High

Close colon: peripheral dissection close to the colon.
Sigmoid vessels: peripheral dissection on sigmoid vessels.
Valdoni's technique of IMA skeletonization ('the adventitia of the inferior mesenteric artery is entered on the posterior aspect of the vessel. Dissection continues in this plane, and all the branches directed to the left and sigmoid colon are divided').
High, ligation of IMA at its origin; low, ligation of the IMA distally to the origin of left colic artery; SE, side-to-end anastomosis; SS, side-to-side anastomosis; EE, end-to-end anastomosis; NR, not reported.

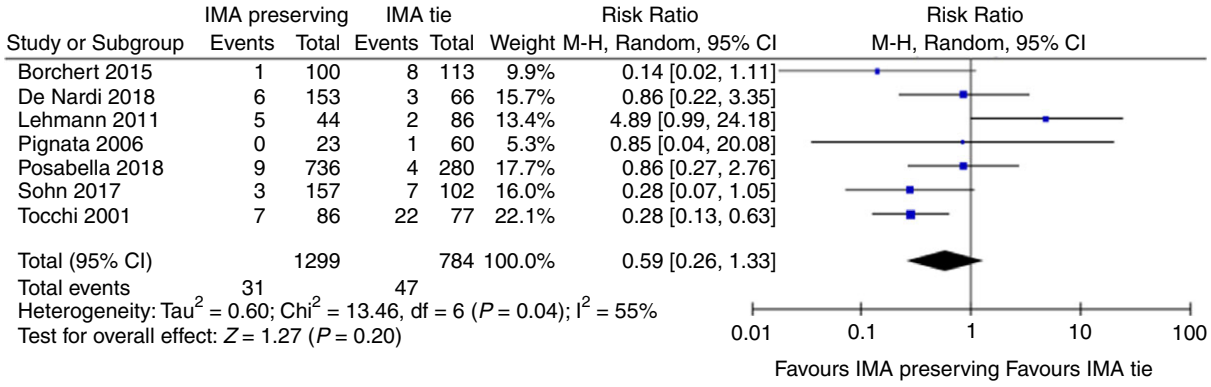

Figure 1 Forest plot showing the anastomotic leakage rate in the IMA preservation group versus the IMA tie (ligation) group.

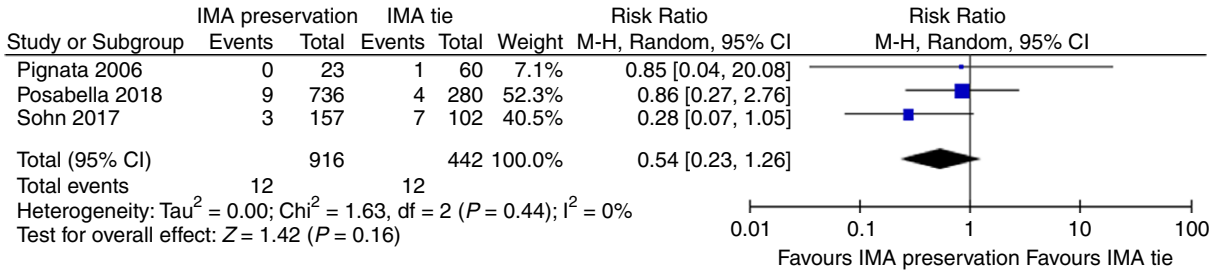

Figure 2 Sensitivity analysis of the studies reporting only laparoscopic resections.

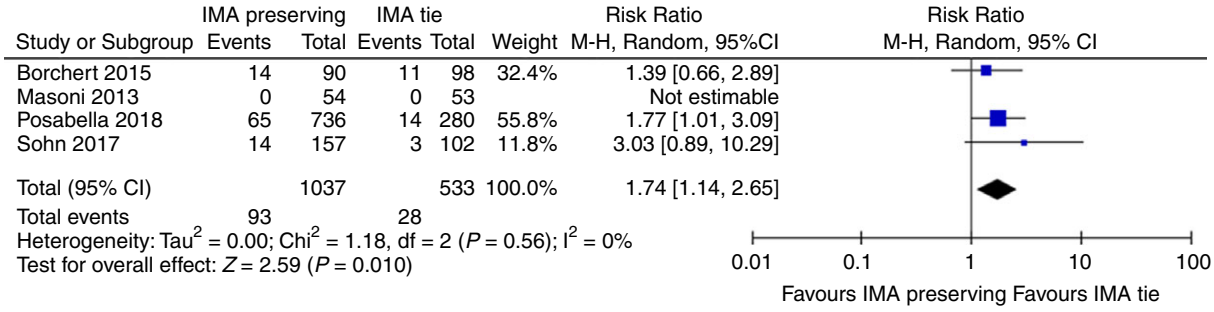

Figure 3 Laparotomy conversion rate.

reported in some studies – ureteric injury, pancreatic injury, rectal bleeding [18], damage to the iliac vessels [20], reoperation [19] and defaecatory disorder/sigmoidectomy syndrome (incontinence score and constipation score) [17]. However, because of insufficient data, they were not pooled into a meta-analysis.

Discussion

The current surgical treatment of diverticular disease includes sigmoidectomy or left hemicolectomy with distal division at the level of the upper rectum. There is no consensus regarding ligation versus preservation of the IMA, which is left to the discretion of the operating surgeon [31]. It has been suggested that preservation of the IMA may decrease the rate of anastomotic leakage after sigmoid resection [32–35]. In 1972, Valdoni described a surgical technique for preservation of the IMA in anterior resection of the rectum, but this technique has not gained popularity [27,36]. Tocchi *et al.* utilized Valdoni's technique during resection of the left colon for diverticular disease: 'using scissors, the IMA adventitia was opened on the posterior aspect of the vessel where no branch emerges and completed on the mesenteric side by ligating and severing any vessel directed to the left and sigmoid colon' [16]. Subsequently, Keighley [37], Schumpelich [38] and Scott-Conner [39] have described other IMA-preserving techniques in their

Table 3 Data and analyses.

Outcomes	Studies	Participants	Statistical method	Effect estimate
Anastomotic leakage	7	2083	RR (M–H, random, 95% CI)	0.59 [0.26, 1.33]
Conversion	4	1570	RR (M–H, random, 95% CI)	1.74 [1.14, 2.65]
Anastomotic bleeding	3	1358	RR (M–H, random, 95% CI)	2.55 [0.58, 11.20]
Bowel injury	2	1275	RR (M–H, random, 95% CI)	1.43 [0.19, 10.59]
Splenic damage	2	1275	RR (M–H, random, 95% CI)	1.37 [0.22, 8.63]

RR, risk ratio; M–H, Mantel–Haenszel method.

classic surgical textbooks. These recent techniques are very different from Valdoni's technique performed by Tocchi *et al.* [16] and Pignata [22] and are technically easier – the dissection is performed peripherally in the sigmoid mesocolon (at the level of the sigmoid vessels or close to the colon). Keighley reported that 'it is probably safer to divide the vessels peripherally rather than attempt a high pedicle ligation; hence the superior haemorrhoidal vessels are preserved' [37]. In the experience of Schumpelich, the skeletonization of the sigmoid mesentery is performed either by UltraScision® or by selective identification of the vessels between endoclips, after which the dissection may proceed close to the bowel wall [38]. During an IMA-preserving sigmoid resection, Scott-Conner and colleagues suggested that peripheral dissection with ligation close to the colon is associated with safe vessel ligation 'Because there is no need to perform a high lymphovascular dissection in the absence of cancer, the mesentery may be divided at a point much closer to the bowel unless the mesentery is so inflamed and edematous it cannot hold ligatures' [39].

In the 1990's, Killingback suggested instead that, during the treatment of diverticular disease, IMA ligation is 'similar to cancer surgery, as there is no advantage in ligating branches and tributaries of sigmoid vessels closer to the intestinal wall' [40]. Many laparoscopic surgeons also prefer the proximal IMA ligation (high tie) [41], which appears to be easier to achieve than the IMA-preserving technique and is familiar from standard cancer resection techniques [42].

More recently, some surgeons have proposed a tailored approach regarding division of the IMA (high tie versus preservation) during open [43] or hand-assisted laparoscopic sigmoidectomy [44]: 'focal segmental resection for benign disease can be accomplished by dividing the vessels close to bowel wall, without the need for a high pedicle transection. A complete sigmoidectomy includes transection of inferior mesenteric artery (IMA) and its origin and resection of the superior hemorrhoidal artery (SHA) and sigmoidal branches' [44].

These different surgical techniques for IMA ligation or preservation were classified by Ambrosetti and Gervaz into four groups [45]:

1. proximal (high) ligation at the origin of IMA;
2. distal (low) ligation below the origin of left colic artery (LCA);
3. preservation of the IMA with division of the LCA
4. preservation of the IMA without division of the LCA.

As suggested by Kit *et al.* [46], a high IMA ligation may be required to ensure a tension-free anastomosis if this is planned to be low in the pelvis. A low IMA ligation is performed distal to the origin of the left colic artery, ensuring preservation of the blood supply to the remaining descending colon.

Most surgeons prefer a tailored approach depending on the extent of the resection [40,47] – a low ligation is the most frequent approach for segmental sigmoid resection [48], whereas a high ligation is preferred if a more extensive colorectal resection with low pelvic anastomosis is needed.

The present meta-analysis failed to show significant differences in outcomes between preservation and ligation of the IMA. Preservation of the IMA was associated with a lower rate of anastomotic leakage, but this did not reach statistical significance. However, the RCTs revealed different results. Masoni *et al.* reported a significantly lower rate of defaecation disorders and lifestyle alteration in the IMA preservation group [17]. Tocchi *et al.* found a significantly lower rate of anastomotic leakage in the IMA preservation group (2.3% *vs* 10.4%, OR 0.22) [16].

The present results, however, should be interpreted with caution due to the limitations of the analysis: the poor methodological quality of the two RCTs, the retrospective design of four out of eight of the included studies, the presence of significant selection bias, different severities of diverticular disease, different types of access (open or laparoscopic), inclusion of elective and emergency resections, and rates of a covering stoma.

Except in a retrospective design, selection bias may occur as a consequence of unclear factors influencing the decision to perform preservation or ligation in the non-RCTs. Another possible source of bias is the experience of the operating surgeon. The rate of defaecatory disorder/sigmoidectomy syndrome (incontinence score and constipation score) was only reported by Masoni *et al.* [17], but the data are not reliable because of a lack of information regarding preoperative status and quality of life. Another important limitation of this meta-analysis is the small sample size.

The heterogeneity was high in the overall analysis compared with low levels in the sensitivity analysis of the three studies reporting laparoscopic resections [18,20,22].

From a practical point of view, IMA preservation is not always straightforward, especially with a laparoscopic approach. The thickened sigmoid mesocolon in chronic diverticular disease may hamper the identification of the ureters and hypogastric nerves. High ligation of the IMA may be easier than low ligation in these cases [49], but this difference did not generate any heterogeneity in the present analysis. On the other hand, a significantly higher rate of conversion in the IMA preservation group was found. Another aspect that is not addressed in the available literature is the role of laparoscopic IMA preservation/ligation in the emergency setting and during Hartmann's procedure [50]. With this in mind, the influence of IMA preservation on the operating time and on anastomotic leakage after Hartmann's reversal deserves further exploration.

No consensus regarding division of the IMA during surgery for diverticular disease exists in current practice. The American Society of Colon and Rectal Surgeons [31] stated: 'in theory, preservation of the superior hemorrhoidal blood supply to the rectum may improve blood flow to the distal side of the colorectal anastomosis and may reduce the risk of anastomotic failure'. IMA preservation is recommended by the Danish National Guidelines [51], the World Emergency Society [52], the Deutschen Gesellschaft für Allgemein- und Viszeralchirurgie [53], the Società Italiana dei Chirurgi Universitari [54] and the Association of Polish Surgeons [55], whereas the Italian Society of Colon and Rectal Surgery [56] reported that there is limited evidence to recommend preservation of the IMA.

Conclusion

This meta-analysis failed to demonstrate a statistically significant benefit of IMA preservation compared with ligation in the primary outcome of anastomotic leakage rate. This, however, may be a consequence of an insufficient sample size and high heterogeneity of patients, severity of diverticular disease, selection bias and variable surgical experience. On the other hand, the RCTs revealed lower rates of anastomotic leakage and defaecatory disorders after IMA preservation. It is important to note, however, that this technique may not be feasible in all patients due to inflammatory changes of the sigmoid mesentery or in frail patients because it may require a longer operative time. Finally, in some cases, laparoscopic IMA preservation may require advanced laparoscopic skills. In fact, in the present study it was associated with a significantly higher rate of conversion than observed in the IMA ligation group.

To date, there is insufficient evidence to recommend IMA preservation as a mandatory approach in surgery for left-sided colonic diverticulitis, and the decision remains at the discretion of the operating surgeon. Nonetheless, a balanced approach is required. In an emergency setting, a high ligation is warranted in cases with uncertainty regarding the diagnosis, when cancer cannot be excluded. On the other hand, IMA preservation may help avoid autonomic nerve injury and may reduce the risk of sexual or functional urinary bladder dysfunction in cases where the diagnosis is clear.

Conflicts of interest

There is no conflict of interest to declare.

Author contributions

RC designed and had the original concept for the manuscript, performed the interpretation of data, drafted and critically revised the manuscript. GP designed, and critically revised the manuscript. GB designed, drafted and revised the manuscript. BH and KT analysed the data and revised the manuscript. KT took part in the interpretation of data and revised the manuscript. SD and JD took part in the data analysis and interpretation and critically revised the manuscript. All authors read and approved the final manuscript and they agree to be accountable for all aspects of the work in ensuring that questions related to the accuracy or integrity of any part of the work are appropriately investigated and resolved.

References

1 Mutch MG. (2013). Laparoscopic left colectomy. In: *Atlas of Surgical Techniques for the Colon, Rectum, and Anus* (eds Fleshman J, Birnbaum E, Hunt SR, Konder JK, Linn A, Mutch MG, Safar B). Saunders, Philadelphia, PA, USA.

2 Ke J, Cai J, Wen X *et al.* Anatomic variations of inferior mesenteric artery and left colic artery evaluated by 3

dimensional CT angiography: Insights into rectal cancer surgery. A retrospective observational study. *Int J Surg* 2017; **41:** 106–11.

3 Boutros M, Gordon PH. (2017). Inferior mesenteric artery. In: *Current Therapy in Colon and Rectal Surgery* (eds Fazio VW, Church JM, Delaney C, Kiran RP). Elsevier, Philadelphia, PA, USA.

4 Standring S. Vascular supply and lymphatic drainage of the hindgut. In: *Gray's Anatomy. The Anatomical Basis of Clinical Practice* (ed. Standring S). Philadelphia, PA, USA: Elsevier, 2016. pp. 1150–1152.

5 Drake RL, Vogl AW, Mitchell AM. (2012). Arterial supply to the gastrointestinal tract. In: *Gray's Basic Anatomy* (ed Standring S). Elsevier, Philadelphia, PA, USA.

6 De Martino RR. (2015). Normal and variant mesenteric anatomy. In: *Mesenteric Vascular Disease: Current Therapy* (ed Oderich GS). Springer Science, New York, NY, USA.

7 Lange MM, Buunen M, van de Velde CJ, Lange JF. Level of arterial ligation in rectal cancer surgery: low tie preferred over high tie. A review. *Dis Colon Rectum* 2008; **51:** 1139–45.

8 Yang Y, Wang G, He J, Zhang J, Xi J, Wang F. High tie versus low tie of the inferior mesenteric artery in colorectal cancer: a meta-analysis. *Int J Surg* 2018; **52:** 20–4.

9 Khalil HA, Yoo J. Colorectal emergencies: perforated diverticulitis (operative and nonoperative management). *J Gastrointest Surg* 2014; **18:** 865–8.

10 Letarte F, Brown CJ. (2018). Perforated diverticulitis: what are the options for resection? In: *Current Common Dilemmas in Colorectal Surgery* (eds Schlachta CM, Sylla P). Springer International Publishing, New York, NY, USA.

11 Levack MM, Savitt LR, Berger DL *et al.* Sigmoidectomy syndrome? Patients' perspectives on the functional outcomes following surgery for diverticulitis. *Dis Colon Rectum* 2012; **55:** 10–7.

12 Cirocchi R, Trastulli S, Farinella E *et al.* Is inferior mesenteric artery ligation during sigmoid colectomy for diverticular disease associated with increased anastomotic leakage? A meta-analysis of randomized and non-randomized clinical trials. *Colorectal Dis* 2012; **14:** 521–9.

13 Moher D, Liberati A, Tetzlaff J, Altman DG, PRISMA Group. Preferred reporting items for systematic reviews and meta-analyses: the PRISMA statement. *J Clin Epidemiol* 2009; **62:** 1006–12.

14 Higgins J.P.T., Green S. (2011) Cochrane Handbook for Systematic Reviews of Interventions Version 5.1.0[updated March 2011]. The Cochrane Collaboration.

15 Slim K, Nini E, Forestier D, Kwiatkowski F, Panis Y, Chipponi J. Methodological index for non-randomized studies (minors): development and validation of a new instrument. *ANZ J Surg* 2003; **73:** 712–6.

16 Tocchi A, Mazzoni G, Fornasari V, Miccini M, Daddi G, Tagliacozzo S. Preservation of the inferior mesenteric artery in colorectal resection for complicated diverticular disease. *Am J Surg* 2001; **182:** 162–7.

17 Masoni L, Mari FS, Nigri G *et al.* Preservation of the inferior mesenteric artery via laparoscopic sigmoid colectomy performed for diverticular disease: real benefit or technical challenge: a randomized controlled clinical trial. *Surg Endosc* 2013; **27:** 199–206.

18 Posabella A, Rotigliano N, Tampakis A, von Flüe M, Füglistaler I. Peripheral vs pedicle division in laparoscopic resection of sigmoid diverticulitis: a 10-year experience. *Int J Colorectal Dis* 2018; **33:** 887–94.

19 Borchert DH, Schachtebeck M, Schoepe J *et al.* Observational study on preservation of the superior rectal artery in sigmoid resection for diverticular disease. *Int J Surg* 2015; **21:** 45–50.

20 Sohn M, Schlitt HJ, Hornung M *et al.* Preservation of the superior rectal artery: influence of surgical technique on anastomotic healing and postoperative morbidity in laparoscopic sigmoidectomy for diverticular disease. *Int J Colorectal Dis* 2017; **32:** 955–60.

21 Lehmann RK, Brounts LR, Johnson EK, Rizzo JA, Steele SR. Does sacrifice of the inferior mesenteric artery or superior rectal artery affect anastomotic leak following sigmoidectomy for diverticulitis? a retrospective review. *Am J Surg* 2011; **201:** 623–7.

22 Pignata G. Laparoscopic treatment for acute diverticular disease. *Acta Chir Iugosl* 2006; **53:** 19–22.

23 De Nardi P, Gazzetta P. Does inferior mesenteric artery ligation affect outcome in elective colonic resection for diverticular disease? *ANZ J Surg* 2018; **88:** E778–81.

24 Fegiz G, Tonelli F, Rossi P, Di Paola M, De Masi E, Simonetti G. Preservation of the superior hemorrhoidal artery in resection of the colon and rectum. *Surg Gynecol Obstet* 1976; **143:** 919–25.

25 Napolitano AM, Napolitano L, Costantini R, Ucchino S, Innocenti P. Skeletization of the inferior mesenteric artery in colorectal surgery. Current considerations. *G Chir* 1996; **17:** 185–9.

26 Messinetti S, Giacomelli L, Manno A *et al.* Preservation and peeling of the inferior mesenteric artery in the anterior resection for complicated diverticular disease. *Ann Ital Chir* 1998; **69:** 479–82.

27 Valdoni P, Virno F, Aureggi A. Preservation and peeling of the inferior mesenteric artery as a complication-preventing technique in the anterior resection of the rectum. *Surg Italy* 1972; **2:** 85–9.

28 Bergamaschi R, Lovvik K, Marvik R. Preserving the superior rectal artery in laparoscopic sigmoid resection for complete rectal prolapse. *Surg Laparosc Endosc Percutan Tech* 2003; **13:** 374–6.

29 Wakahara T, Toyokawa A, Ashitani H, Tsuchida S, Hasegawa Y. Comparison of laparoscopic sigmoidectomy with and without preservation of the superior rectal artery: a single-institution retrospective study. *Asian J Endosc Surg* 2015; **8:** 29–33.

30 Trencheva K, Morrissey KP, Wells M *et al.* Identifying important predictors for anastomotic leak after colon and rectal resection: prospective study on 616 patients. *Ann Surg* 2013; **257:** 108–13.

31 Feingold D, Steele SR, Lee S *et al.* Practice parameters for the treatment of sigmoid diverticulitis. *Dis Colon Rectum* 2014; **57:** 284–94.

32 McDermott FD, Heeney A, Kelly ME, Steele RJ, Carlson GL, Winter DC. Systematic review of preoperative, intraoperative and postoperative risk factors for colorectal anastomotic leaks. *Br J Surg* 2015; **102:** 462–79.
33 Stocchi L. Current indications and role of surgery in the management of sigmoid diverticulitis. *World J Gastroenterol* 2010; **16:** 804–17.
34 Ghavami D. Doit-on préserver l'artére mesentérique inférieure lors d'une sigmoidectomie por maladie benigne? *J Coelio-chirurgie* 2008; **65:** 11–4.
35 Collins D, Winter DC. Laparoscopy in diverticular disease: controversies. *Best Pract Res Clin Gastroenterol* 2014; **28:** 175–82.
36 Nardi G. (1976). Anterior rectocolic resection. In: *Abdominal Surgery: an Atlas of Operative Techniques by Pietro Valdoni* (ed Nardi GL). Saunders, Milan, Italy.
37 Keighley W. (2008). Colonic diverticular disease. In: *Surgery of the Anus – Rectum and Colon* (ed Keighley W). Saunders, Philadelphia, PA, USA.
38 Schumpelich V. (2009). Tubular resection of the sigmoid colon. In: *Atlas of General Surgery* (ed Schumpelich V). Thieme, Stuttgart, Germany.
39 Scott-Conner C. (2006). Operation for colonic diverticulitis. In: *Chassin's Operative Strategy in Colon and Rectal Surgery* (eds Scott-Conner C, Carol EH). Springer, New York, NY, USA.
40 Killingback M. (1993). Elective surgery for sigmoid diverticular disease. In: *Rob and Smith Operative Surgery of the Colon, Rectum and Anus* (eds Fielding LP, Goldberg SM). Chapman & Hall Medical, London, UK.
41 Regenbogen SE. (2015). Surgical management of complicated diverticulitis: perforation and colovescical fistula. In: *Operative Techniques in Colon and Rectal Surgery* (eds Albo D, Muhlholland ME). Wolters Klower Healths, Philadelphia, PA, USA.
42 Morris AM. (2015). Sigmoid colectomy: laparoscopic technique. In: *Operative Techniques in Colon and Rectal Surgery* (eds Albo D, Muhlholland ME). Wolters Klower Healths, Philadelphia, PA, USA.
43 Frederick WAI, Oyetunji T, Seetahai S. (2015). Sigmoid colectomy: open technique. In: *Operative Techniques in Colon and Rectal Surgery* (eds Albo D, Muhlholland ME). Wolters Klower Healths, Philadelphia, PA, USA.
44 Anaya D.A., Albo D. Hand-assisted laparoscopic sigmoidectomy. In: *Operative Techniques in Colon and Rectal Surgery* (eds Albo D, Muhlholland ME). Philadelphia, PA, USA: Wolters Klower Healths.
45 Ambrosetti P, Gervaz P. Laparoscopic elective sigmoidectomy for diverticular disease: a plea for standardization of the procedure. *Colorectal Dis* 2014; **16:** 90–4.
46 Kit CW, Lieske B, Lim FSH. (2014). Emergency surgery for perforative sigmoid colonic diverticulitis. In: *Atlas of Complicated Abdominal Emergencies: Tips on Laparoscopic and Open Surgery, Therapeutic Endoscopy and Interventional Radiology* (eds Kong TT, Lomanto D). Singapore, Republic of Singapore: World Scientific, https://www.worldscientific.com/
47 Killingback M. (2005). Surgical treatment of diverticulitis. In: *Current Therapy in Colon and Rectal Surgery* (eds Fazio VW, Church JM, Delaney CP). Mosby Inc, Philadelphia, PA, USA.
48 Lamy J. (1969) Colectomies pour lesions inflammatories. In: *Nouveau Traite' de Technique Chirurgicale. XI: Intestin Grele – Colon – Rectum – Anus* (eds Lamy J, Louis R, Michotey G, Bricot R, Sarles JCL). Paris, France: Masson.
49 Leroy J (2005), Laparoscopic sigmoidectomy for diverticulitis. WeBSurg, 5: http://www.websurg.com/doi-vd01en1782e.htm.
50 Cirocchi R, Fearnhead N, Vettoretto N *et al.* The role of emergency laparoscopic colectomy for complicated sigmoid diverticulitis: a systematic review and meta-analysis. *The Surgeon* 2018; 1–10. https://doi.org/10.1016/j.surge.2018.08.010.
51 Andersen JC, Bundgaard L, Elbrond H, Laurberg S, Walker LR, Stovring J. Danish national guidelines for treatment of diverticular disease. *Dan Med J* 2012; **59:** 4453.
52 Moore FA, Catena F, Moore EE, Leppaniemi A, Peitzmann AB. Position paper: management of perforated sigmoid diverticulitis. *World J Emerg Surg* 2013; **8:** 55.
53 Leifeld L, Germer CT, Böhm S *et al.* S2k guidelines diverticular disease/diverticulitis. *Z Gastroenterol* 2014; **52:** 663–710.
54 Tonelli F., Di Carlo V., Liscia G., Serventi A. (2009), Diverticular disease of the colon: diagnosis and treatment. Consensus Conference, 5th National Congress of the Italian Society of Academic Surgeons. *Ann Ital Chir*, **80:**3–8.
55 Pietrzak A, Bartnik W, Szczepkowski M *et al.* Interdisciplinary consensus on diagnostics and treatment of colonic diverticulosis. *Pol Przegl Chir* 2015; **87:** 203–20.
56 Binda GA, Cuomo R, Laghi A *et al.* Italian Society of Colon and Rectal Surgery, Practice parameters for the treatment of colonic diverticular disease: italian Society of Colon and Rectal Surgery (SICCR) guidelines. *Tech Coloproctol* 2015; **19:** 615–26.

Supporting Information

Additional Supporting Information may be found in the online version of this article:

Appendix S1. PRISMA flow diagram.

Appendix S2. Risk of bias of the RCTs.

Appendix S3. Assessment of the methodological quality of the included studies with the MINORS scale.

Appendix S4. (a) Characteristics of diverticular disease in the included patients. (b) Characteristics of acute diverticulitis: Hansen–Stock classification.

Appendix S5. Exclusion criteria.

Appendix S6. Definition of anastomotic leakage.